

## The management of tennis elbow

John Orchard,<sup>1</sup> Alex Kountouris<sup>2</sup>

<sup>1</sup>School of Public Health, University of Sydney, NSW 2006, Australia

<sup>2</sup>Australian Cricket Team, Melbourne, Australia

Correspondence to: J Orchard [johnorchard@msn.com.au](mailto:johnorchard@msn.com.au)

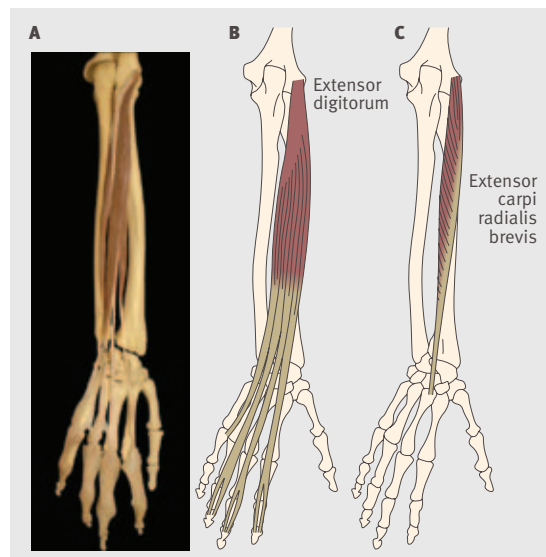
Cite this as: *BMJ* 2011;342:d2687  
doi: 10.1136/bmj.d2687

Tennis elbow is a tendinopathy of the common extensor origin (fig 1) of the lateral elbow. Although the pathology is in the elbow region, patients present with gradual onset of pain on extension movements of the wrist and fingers and supination of the forearm. The condition was formerly known as “lateral epicondylitis.” Because the pathology is no longer thought to be inflammatory, the “itis” suffix is a misnomer,<sup>1 2</sup> and it is more accurately described as a partially reversible but degenerative overuse-underuse tendinopathy. Because of the length of this term, most clinicians prefer to use the informal name “tennis elbow.” The condition is usually easy to diagnose on clinical presentation (imaging is rarely needed to exclude coexisting elbow joint pathology) but much harder to cure. The clinical features are tenderness at the lateral epicondyle, normal elbow range of motion, and pain on resisted movements (particularly resisted third finger extension). If the elbow’s range of motion is restricted, other diagnoses should be considered because the loss of range suggests joint pathology.

The cause of the injury varies, but altered loading patterns are a common theme. Most patients don’t play tennis, but when the injury is caused by playing tennis it is the backhand stroke that leads to excessive loading of the tendons at the common extensor origin. Since racquet frames became lighter and coaches started teaching the double handed backhand stroke, tennis elbow has become less common in tennis players. Many tennis players have a weekly training and playing routine that regularly loads the tendons and keeps them healthy. More typically the injury occurs in people who have been sedentary for years and then begin exercising at the gym, start doing some gardening, paint a room, lift a new baby, or even just carry heavy luggage on holiday and overuse a previously underused and atrophied tendon. Tennis players, people who exercise regularly, and working tradespeople who regularly load the tendon are also at risk of injury if the load increases or they decrease rest periods between loads.

**bmj.com** Previous articles in this series

- ▶ Diagnosis and management of schistosomiasis (*BMJ* 2011;342:d2651)
- ▶ Advising on travel during pregnancy (*BMJ* 2011;342:d2506)
- ▶ Laser refractive eye surgery (*BMJ* 2011;342:d2345)
- ▶ Management of paracetamol poisoning (*BMJ* 2011;342:d2218)



**Fig 1** | (A) Anatomical view of the left forearm bones and the extensor digitorum muscles (posterior view with forearm in supination); the common extensor origin can be seen at the lateral epicondyle just above the elbow joint at the top right. Diagrams of the left extensor digitorum muscle (B; superficial) and extensor carpi radialis brevis muscle (C; deep); in tennis elbow the pathological part of the common extensor tendon is usually at the origin of the extensor carpi radialis brevis muscle; pain is felt particularly on extension of the third finger, which activates both the extensor carpi radialis brevis muscle and the relevant extensor digitorum muscle. Image reproduced, with permission, from Anatomedia ([www.anatomedia.com](http://www.anatomedia.com))

### SOURCES AND SELECTION CRITERIA

We performed a search of PubMed and SPORTDiscus for the terms “tennis elbow” and “lateral epicondyl\*” and extracted what we thought were the most valid reviews and trials of management options, particularly high quality randomised controlled trials performed during the past decade.

### SUMMARY POINTS

Tennis elbow is a tendinopathy of the common extensor origin of the lateral elbow  
Cortisone injections are harmful in the longer term and are no longer recommended in most cases  
Rehabilitation (exercise) based treatment is helpful, but to be effective patients must usually remove tendon overload  
Further research is needed on newer (minimally invasive) treatments, such as platelet-rich plasma injections, hyaluronan gel injections, and nitrate patches  
Reserve surgery and botulinum toxin injections for the worst cases because patients can take six months to return to full function  
Many cases of tennis elbow cases will naturally resolve in 6-12 months

### What is the mechanism of injury?

As with other tendinopathies the pathology in tennis elbow is complex and not fully understood. Some general principles of tendon mechanics and homeostasis apply. Tendons act as “springs” to make muscle movement more efficient, and their recoil (spring effect) increases with higher load, being most efficient when the tendon is close to, but not quite at, its failure point. Tendons will strengthen when the demand on them is greater and weaken naturally when they are less used. Healthy tendons can strengthen easily in response to gradual increases in load but can fail if the

loading increase is too sudden or too great. Sudden overload may alter a tendon's structure and allow a degenerative process to begin. A recent review of the mechanism of tendon injury described tendinopathy as being on a continuum that accounts for heterogeneity in presentation, with phase of injury (initial reactive tendinopathy, to tendon disrepair, to degenerative tendinopathy) largely dependent on the length of time that a tendon has been unable to cope with an increased load.<sup>3</sup>

### How is tennis elbow treated?

#### Rehabilitation and graduated loading

Overload and underload are both bad for tendons. The fundamental principle underpinning any management programme for tennis elbow is to exercise (load) the tendon as close to its limits as possible, without exceeding them. Since eccentric (lengthening only) exercises were reported to improve pain and function in patients with chronic Achilles tendinopathy, this type of exercise (fig 2) has become the mainstay of rehabilitation programmes for most tendinopathies,<sup>4 5</sup> including tennis elbow.<sup>6-8</sup> In our clinical practice, patients who have stopped acutely overloading the tendon and whose pain is slightly settling do very well with eccentric exercises. The partial loading provided by the exercises helps to repair degenerative tendon tissue and prepare it for future loads. The clinical results are not as good in patients who continue to overload the affected tendon (for example, athletes who continue with their season or workers who continue their normal duties).<sup>9</sup>

#### Oral pain relief and non-steroidal anti-inflammatory drugs

Analgesics and non-steroidal anti-inflammatory drugs can be used to help patients cope with the pain of tennis elbow,




Fig 2 | Eccentric (lengthening contraction only) exercise for right tennis elbow (wrist extensors), see video on [bmj.com](http://bmj.com)

which is hopefully temporary. These drugs do not improve the long term outcome of the condition. Although the long term effects have not been studied, in theory non-steroidal anti-inflammatory drugs may have deleterious effects on tendon healing (similar to cortisone injections).

#### Do cortisone injections help?

Evidence from randomised controlled trials now confirms the theoretical objections to using cortisone injections to treat tendinopathies like tennis elbow.<sup>2 10</sup> A landmark trial compared cortisone injections, physiotherapy (mobilisation with movement), and a wait and see approach in 198 patients with untreated tennis elbow and found that despite promising results for cortisone injections in the short term, in the longer term patients treated with hydrocortisone were more likely to have a recurrence.<sup>8</sup> In most circumstances, cortisone injections should not be used.<sup>11</sup> Cortisone leads to very good results in the short term (six weeks) but is harmful in the longer term (more than three months).<sup>8 10</sup> The short term outcome may be more important than the longer term for some patients—for example, a student whose doctoral thesis must be submitted within six weeks or a tennis professional competing in his or her last grand slam tournament. However, for most patients, long term prognosis is important so cortisone should be avoided.

#### Glyceryl trinitrate patches

One good quality randomised trial from 2003 found that topical glyceryl trinitrate patches applied over the painful area act as a local and systemic vasodilator and improved outcomes in the first six months compared with placebo.<sup>12</sup> Longer term results have not shown benefit over placebo, although unlike cortisone injections no long term harm was seen.<sup>13 14</sup> Patches must be prescribed “off-label,” and because the required dose is smaller than the usual dose for angina, a brand that can be cut into small pieces must be used. Side effects include dizziness and headaches through vasodilation induced hypotension, particularly in younger people; older patients may welcome the side effect of lower blood pressure.

#### Autologous platelet-rich plasma injections

Clinicians and researchers have recently investigated injections of autologous blood products for tendinopathy, including platelet-rich-plasma (PRP). PRP injections involve drawing blood from the patient, centrifuging the sample, and then injecting the heaviest layer of plasma (which has a higher concentration of platelets) back into the patient. A recent high quality randomised controlled trial that compared autologous PRP injections with cortisone injections found superior cure rates and pain scores for PRP injections up to two years after treatment,<sup>15 16</sup> confirming encouraging findings from previous lower quality studies.<sup>17</sup> These studies imply that either PRP is helpful for tennis elbow or cortisone is bad for tennis elbow. Both statements could be true, but there is no consensus yet on whether PRP significantly improves good conservative management. Uncertainties about PRP and related treatments (dry needling, prolotherapy, and treatment with autologous blood, autologous tenocytes, or stem cells)

### A PATIENT'S PERSPECTIVE

A 44 year old female worker at a bookstore returned from a three week holiday with lateral right elbow pain. She reported some pain on lifting books at work with her forearm pronated but not with it supinated. She also reported pain using a computer mouse and turning taps and door handles. On clinical testing she had localised tenderness at the insertion of the common extensor tendon and pain with resisted wrist and middle finger extension. Grip and forearm supination strength were reduced compared with the other arm. She also had poor scapular stability and weakness in shoulder external rotators. A diagnosis of tennis elbow was made on the basis of her clinical assessment. Radiography and ultrasound were considered the first line investigations, but were not needed in this case. The pain was limited by paracetamol (acetaminophen) during the working day, but the condition didn't affect her when not loading the right arm. The initial aim of her management was to reduce tendon load, which was achieved by educating her about the pathology and activities that would overload the tendon. She reduced her lifting activities and limited the amount of time spent using a computer. As her pain gradually subsided because of the load reduction, formal eccentric exercises (fig 2) were started, increasing in intensity gradually as guided by pain, although she was not discouraged from performing exercises with a low degree of pain (<5 out of 10 pain on subjective assessment). Simultaneously, scapular and shoulder stability exercises were also recommended.

She was advised that she should gradually start lifting books and using a computer for more prolonged periods once pain from clinical testing and daily activities had improved and when her forearm muscle strength was restored. She was told about the importance of maintaining the rehabilitation programme, even after she returned to full work duties and that other treatments were available, such as platelet rich plasma injections and nitrate patches, if the recovery halted or the pain worsened.

include whether outcomes differ between these treatments and whether a peri-tendinous or ultrasound guided injection aimed at the injured part of the tendon would improve outcomes. Because these newer treatments can be expensive, superior results need to be demonstrated to justify the extra costs.

#### Hyaluronan gel injection

Hyaluronan gel is an interesting new injection option that is more commonly used in osteoarthritis. A recent randomised controlled trial found that periarticular injections of sodium hyaluronate were superior to placebo injections (in terms of pain) in patients with tennis elbow.<sup>10 18</sup> Tennis elbow may therefore have a greater joint pathology component than was previously thought, but it could be that degenerative tendon and cartilage have much in common. Animal studies have suggested a role for hyaluronan in improving tendon healing.<sup>19 20</sup>

#### Botulinum toxin A injection

Botulinum toxin A, injected into the extensor digitorum longus muscles for the third and fourth fingers to paralyse them, has been shown to be an effective treatment for tennis elbow.<sup>21 22</sup> Paralysis presumably forces unloading of the extensor tendon, followed by graduated reloading as the effects of the toxin gradually wear off. The major disadvantage of this treatment is that patients cannot extend their third and fourth fingers for many months afterwards, which is disabling, although not to the same extent as surgery. Thus injection of botulinum toxin may be considered in patients whose symptoms are severe enough for them to be considering surgery.<sup>23</sup>

#### Surgery

Surgery has a role in cases of tennis elbow that do not respond to a sustained period of conservative treatment.<sup>24</sup>

### ADDITIONAL EDUCATIONAL RESOURCES

- Cyriax JH. The pathology and treatment of tennis elbow. *J Bone Joint Surg Am* 1936;18:921-40. [www.ejbs.org/cgi/reprint/18/4/921](http://www.ejbs.org/cgi/reprint/18/4/921) (historical article from 1936)
- Nirschl RP, Pettrone FA. Tennis elbow. The surgical treatment of lateral epicondylitis. *J Bone Joint Surg Am* 1979;61:832-9. [www.ejbs.org/cgi/reprint/61/6/832](http://www.ejbs.org/cgi/reprint/61/6/832) (classic surgical paper)
- Bisset L, Beller E, Jull G, Brooks P, Darnell R, Vicenzino B. Mobilisation with movement and exercise, corticosteroid injection, or wait and see for tennis elbow: randomised trial. *BMJ* 2006;333:939. [www.bmj.com/content/333/7575/939.long](http://www.bmj.com/content/333/7575/939.long) (landmark randomised controlled trial showing poor long term results of cortisone injections)
- YouTube ([www.youtube.com/watch?v=9nhHjP4kY4](http://www.youtube.com/watch?v=9nhHjP4kY4))—Video discussing the randomised controlled trial on eccentric exercises for tennis elbow
- Tennis Elbow Therapies (<http://tennis-elbow-therapies.com/>)—Several videos on tennis elbow
- Anti-inflammatory drugs. [www.injuryupdate.com.au/images/research/NSAIDcortisoneuse.pdf](http://www.injuryupdate.com.au/images/research/NSAIDcortisoneuse.pdf) (summaries of the positive and negative effects of non-steroidal anti-inflammatory drugs and cortisone in sports medicine)

Because of the low level of evidence to support surgery and because tennis elbow usually resolves within 12 months, it makes sense to wait at least this long before considering surgery. All techniques described probably work in a similar manner to botulinum toxin, by forcing an initial rest on the patient who then gradually reloads the tendon as the pain of the surgery diminishes.

#### Extracorporeal shock wave treatment

Extracorporeal shock wave treatment (lithotripsy) may help in tendinopathies with ectopic calcification in the tendon,<sup>25</sup> but randomised trials have not found it to be beneficial in regular cases of tennis elbow.<sup>26-28</sup> For reasons not well understood, calcification commonly forms stalagmites up from the bone in tendinopathies of the Achilles, quadriceps, triceps, and supraspinatus. Stalactite calcifications are rare in pathological tendons that head downwards, such as tennis elbow. In the rare scenario of calcification being demonstrated in a common extensor origin tendon, extracorporeal shock wave treatment may be useful.

### Conclusion

With a modern evidence based approach to management we can reassure patients that the long term prognosis for both reduction of pain and return to function is good, even if recovery from tennis elbow tends to be frustratingly slow.

**Contributors:** JO is the main author and guarantor; AK reviewed and provided the initial draft of the sections on rehabilitation and tendon pathology.

**Funding:** None received.

**Competing interests:** All authors have completed the Unified Competing Interest form at [www.icmje.org/coi\\_disclosure.pdf](http://www.icmje.org/coi_disclosure.pdf) (available on request from the corresponding author) and declare: no support from any organisation for the submitted work; JO has been paid by GlaxoSmithKline Consumer Products (Australia) to deliver lectures at pharmacy conferences recommending that non-steroidal anti-inflammatory drugs should not be an automatic first line treatment for treating sports injuries; no other relationships or activities that could appear to have influenced the submitted work.

**Provenance and peer review:** Not commissioned; externally peer reviewed. Patient consent obtained for fig 2; patient consent not required (patient anonymised, dead, or hypothetical) for patient's perspective box.

- 1 Khan KM, Cook JL, Bonar F, Harcourt P, Astrom M. Histopathology of common tendinopathies. Update and implications for clinical management. *Sports Med* 1999;27:393-408.
- 2 Khan KM, Cook JL, Kannus P, Maffulli N, Bonar SF. Time to abandon the "tendinitis" myth. *BMJ* 2002;324:626-7.
- 3 Cook JL, Purdam CR. Is tendon pathology a continuum? A pathology model to explain the clinical presentation of load-induced tendinopathy. *Br J Sports Med* 2009;43:409-16.
- 4 Stanish WD, Rubinovich RM, Curwin S. Eccentric exercise in chronic tendinitis. *Clin Orthop Relat Res* 1986;208:65-8.
- 5 Alfredson H, Pietila T, Jonsson P, Lorentzon R. Heavy-load eccentric calf muscle training for the treatment of chronic Achilles tendinosis. *Am J Sports Med* 1998;26:360-6.
- 6 Tyler T, Thomas G, Nicholas S, McHugh M. Addition of isolated wrist extensor eccentric exercise to standard treatment for chronic lateral epicondylitis: a prospective randomized trial. *J Shoulder Elbow Surg* 2010;19:917-22.
- 7 Croisier JL, Foidart-Dessalle M, Tinant F, Crielaard JM, Forthomme B. An isokinetic eccentric programme for the management of chronic lateral epicondylar tendinopathy. *Br J Sports Med* 2007;41:269-75.
- 8 Bisset L, Beller E, Jull G, Brooks P, Darnell R, Vicenzino B. Mobilisation with movement and exercise, corticosteroid injection, or wait and see for tennis elbow: randomised trial. *BMJ* 2006;333:939.
- 9 Visnes H, Hoksrud A, Cook J, Bahr R. No effect of eccentric training on jumper's knee in volleyball players during the competitive season. *Clin J Sports Med* 2005;15:227-34.
- 10 Coombes BK, Bisset L, Vicenzino B. Efficacy and safety of corticosteroid injections and other injections for management of tendinopathy: a systematic review of randomised controlled trials. *Lancet* 2010;376:1751-67.
- 11 Osborne H. Stop injecting corticosteroid into patients with tennis elbow, they are much more likely to get better by themselves! *J Sci Med Sport* 2010;13:380-1.
- 12 Paoloni J, Appleyard R, Nelson J, Murrell G. Topical nitric oxide application in the treatment of chronic extensor tendinosis at the elbow: a randomized, double-blinded, placebo-controlled clinical trial. *Am J Sports Med* 2003;31:915-20.
- 13 McCallum S, Paoloni J, Murrell G. Five-year prospective comparison study of topical glyceryl trinitrate treatment of chronic lateral epicondylitis at the elbow. *Br J Sports Med* 2011;45:416-20.
- 14 Paoloni JA, Murrell GA, Burch RM, Ang RY. Randomized, double-blind, placebo-controlled clinical trial of a new topical glyceryl trinitrate patch for chronic lateral epicondylitis. *Br J Sports Med* 2009;43:299-302.
- 15 Gosens T, Peerbooms JC. Ongoing positive effect of platelet-rich plasma versus corticosteroid injection in lateral epicondylitis: a double-blind randomized controlled trial with 2-year follow-up. *Am J Sports Med* 2011; online 21 March.
- 16 Peerbooms JC, Sluimer J, Bruijn DJ, Gosens T. Positive effect of an autologous platelet concentrate in lateral epicondylitis in a double-blind randomized controlled trial: platelet-rich plasma versus corticosteroid injection with a 1-year follow-up. *Am J Sports Med* 2010;38:255-62.
- 17 Mishra A, Collado H, Fredericson M. Platelet-rich plasma compared with corticosteroid injection for chronic lateral elbow tendinosis. *PM R* 2009;1:366-70.
- 18 Petrella RJ, Cogliano A, Decaria J, Mohamed N, Lee R. Management of tennis elbow with sodium hyaluronate periarticular injections. *Sports Med Arthrosc Rehabil Ther Technol* 2010;2:4.
- 19 De Wit T, de Putter D, Tra WM, Rakhorst HA, van Osch GJ, Hovius SE, et al. Auto-crosslinked hyaluronic acid gel accelerates healing of rabbit flexor tendons in vivo. *J Orthop Res* 2009;27:408-15.
- 20 Yagishita K, Sekiya I, Sakaguchi Y, Shinomiya K, Muneta T. The effect of hyaluronan on tendon healing in rabbits. *Arthroscopy* 2005;21:1330-6.
- 21 Placzek R, Drescher W, Deuretzbacher G, Hempfing A, Meiss A. Treatment of chronic radial epicondylitis with botulinum toxin A. A double-blind, placebo-controlled, randomized multicenter study. *J Bone Joint Surg Am* 2007;89A:255-60.
- 22 Wong S, Hui A, Tong P, Poon D, Yu E, Wong L. Treatment of lateral epicondylitis with botulinum toxin. a randomized, double-blind, placebo-controlled trial. *Ann Intern Med* 2005;43:793-7.
- 23 Keizer SB, Rutten HP, Pilot P, Morre HH, v Os JJ, Verburg AD. Botulinum toxin injection versus surgical treatment for tennis elbow: a randomized pilot study. *Clin Orthop Relat Res* 2002;125:31.
- 24 Nirschl RP. Lateral extensor release for tennis elbow. *J Bone Joint Surg Am* 1994;76:951.
- 25 Furia J. High-energy extracorporeal shock wave therapy as a treatment for insertional Achilles tendinopathy. *Am J Sports Med* 2006;34:733-40.
- 26 Crowther MA, Bannister GC, Huma H, Rooker GD. A prospective, randomised study to compare extracorporeal shock-wave therapy and injection of steroid for the treatment of tennis elbow. *J Bone Joint Surg Br* 2002;84:678-9.
- 27 Ho C. Extracorporeal shock wave treatment for chronic lateral epicondylitis (tennis elbow). *Issues Emerg Health Technol* 2007;96:1-4.
- 28 Staples MP, Forbes A, Ptasznik R, Gordon J, Buchbinder R. A randomized controlled trial of extracorporeal shock wave therapy for lateral epicondylitis (tennis elbow). *J Rheumatol* 2008;35:2038-46.

Accepted: 17 April 2011

**ANSWERS TO ENDGAMES, p 1215.** For long answers go to the Education channel on bmj.com

**ANATOMY QUIZ**

**Computed tomography of the heart**

- A Descending aorta
- B Pulmonary valve
- C Left atrial appendage
- D Left anterior descending artery
- E Left circumflex artery

**ON EXAMINATION QUIZ**

**Assessments used in cardiology**

- Question 1: Answer B is correct.
- Question 2: Answer G is correct.
- Question 3: Answer F is correct.

**STATISTICAL QUESTION**

**Absence of evidence is not evidence of absence**

Answer a is the best description.

**CASE REPORT**

**An elusive cause of black stool**

- 1 Meckel's diverticulum.
- 2 Technetium-99m pertechnetate scintigraphy or "Meckel's scan" was used to help make the diagnosis. Other radiological investigations include small bowel contrast studies, ultrasonography, and computed tomography.
- 3 Complications of Meckel's diverticulum include gastrointestinal bleeding, intussusception, obstruction, perforation, diverticulitis, volvulus, and rarely cancer.
- 4 Surgical resection is the treatment of choice for symptomatic Meckel's diverticulum. This can be achieved by diverticulectomy or segmental small bowel resection and primary anastomosis.